

A Comparison between Ultrasound-guided Short-axis Approach and Oblique Axis Approach for Internal Jugular Venous Cannulation in the Emergency Department

Arin Eliza Sunny^{1*}, Siju Varghese Abraham¹, S. Vimal Krishnan², Punchalil Chathappan Rajeev¹, Babu Urumese Palatty¹

¹Department of Emergency Medicine, Jubilee Mission Medical College and Research Institute, Thrissur, Kerala, India, ²Department of Emergency Medicine, Kasturba Medical College, Manipal Academy of Higher Education, Manipal, Karnataka, India

Abstract

Background: Central venous catheter (CVC) placement is a frequently performed procedure in the emergency department (ED). We aim to compare two different ultrasound (US)-guided techniques, the short-axis (SAX) approach and the oblique axis (OAX) approach for the insertion of internal jugular vein (IJV) catheters in an ED setting. **Methods:** This prospective, observational study was conducted in the ED of a single tertiary care teaching hospital on patients requiring IJV cannulation. CVC placement was done using both the SAX and OAX approaches as per the ED physician's discretion. Outcome measures included acute complications, successful insertion of an IJV catheter, number of attempts, and access times. The Chi-square test was used to compare the study variables (acute complications, number of cannulation attempts, and successful cannulation) between the two approaches. Mann-Whitney *U*-test was applied to compare the mean differences of flash time and cannulation time. **Results:** Sixty patients were enrolled, of which 30 underwent IJV cannulation by the SAX technique and 30 by the OAX technique. We noted a total of 22 acute complications, 56.7% in the SAX group and 16.7% in the OAX group. A significant incidence of posterior venous wall puncture was noted in the SAX group (50.0%). No significant statistical differences were noted on analysis of other outcome measures. **Conclusion:** The OAX approach is a useful alternative technique to IJV cannulation in the ED setting. Further multicentric studies in this domain will be required to consider this technique as the primary approach to US-guided IJV cannulation in the ED setting.

Keywords: Central venous access, emergency department, internal jugular vein, oblique axis approach, ultrasonography

INTRODUCTION

Central venous catheterization plays a paramount role in resuscitation in the emergency department (ED).^[1] It is commonly performed to obtain venous access for central venous pressure (CVP) monitoring, administration of vasoactive drugs, intravenous fluids, total parenteral nutrition, hemodialysis, and in difficult peripheral venous cannulations.^[2]

Over the past decade, increased training and improved competence in bedside ultrasonography (USG) has brought about a significant revolution in the approach to central venous catheterization. Ultrasound (US)-guided central venous catheterization has improved success rates, reduced complication rates, decreased the time required to perform

the procedure, and resulted in overall cost-savings and is now recommended over using the traditional Anatomical Landmark technique.^[1]

Different US imaging approaches such as short-axis (SAX) approach, long-axis (LAX) approach, and oblique axis (OAX) approach have been described, all with its own advantages and disadvantages.^[3-5] The SAX approach employs cannulation of the internal jugular vein (IJV) in the "out of plane" approach wherein the US probe is placed

Address for correspondence: Dr. Arin Eliza Sunny,
Department of Emergency Medicine, Jubilee Mission Medical College and
Research Institute, Thrissur, Kerala, India.
E-mail: erineliza25@gmail.com

Received: 25-02-2021 Revised: 22-04-2021 Accepted: 25-05-2021 Available Online: 21-08-2021

Access this article online

Quick Response Code:



Website:
www.jmuonline.org

DOI:
10.4103/JMU.JMU_49_21

This is an open access journal, and articles are distributed under the terms of the Creative Commons Attribution-NonCommercial-ShareAlike 4.0 License, which allows others to remix, tweak, and build upon the work non-commercially, as long as appropriate credit is given and the new creations are licensed under the identical terms.

For reprints contact: WKHLRPMedknow_reprints@wolterskluwer.com

How to cite this article: Sunny AE, Abraham SV, Krishnan SV, Rajeev PC, Palatty BU. A comparison between ultrasound-guided short-axis approach and oblique axis approach for internal jugular venous cannulation in the emergency department. *J Med Ultrasound* 2022;30:81-6.

perpendicular to the venous anatomy. It allows simultaneous visualization of both artery and vein, but makes needle tip control difficult.^[6,7] The LAX approach, also known as the “in plane” approach, uses a probe orientation in parallel to venous anatomy which optimizes needle visualization, but it can be challenging to perform owing to certain anatomical limitations (such as neck length). In addition, LAX only displays the vein in the US image and if the operator strays medially, accidental arterial cannulation can occur.^[6] The OAX approach, a relatively newer technique, attempts to take advantage of the strengths of both previous approaches using a probe alignment that is midway between SAX and LAX approaches, and combines it with an in-plane needle insertion where the needle is advanced from lateral to medial.^[3] Thus, the OAX approach theoretically optimizes visualization of both the needle and the venous blood vessel with all its encompassing structures.

Studies comparing the SAX and LAX approaches have been done in varied settings with many of them proving the SAX approach to be better in terms of successful cannulation as well as in preventing complications.^[8,9] Studies comparing the SAX approach with the OAX approach are limited and mostly undertaken in settings such as the operating room and critical care. There are no studies comparing the SAX and OAX approach, till date, in the Indian emergency setting. This study aimed to measure and compare the rate of acute complications, success rate, number of attempts to successful cannulation and access times between US-guided SAX approach and OAX approach during IJV catheterization in the ED setting.

MATERIALS AND METHODS

Study design and setting

The study was conducted as a prospective observational study in the ED of a tertiary care teaching hospital (Jubilee Mission Medical College and Research Institute, Kerala, India) over a period of 1 year after independent approval from the Institute's Review Board and Institute's Ethical Committee (IEC no: 51/17/IEC/JMMC and RI). The study was registered under the Clinical Trials Registry-India (CTRI/2019/01/016987).

Study population

We included individuals aged 18 years and older, who required central venous access through IJV as part of their treatment if they consented to be part of the study. The ED physician decided the need for central venous access and the approach to cannulation (SAX or OAX approach) according to the patients' clinical status. The investigator had no role in determining the indication for central venous access, the site of placement or the method, but only recorded the parameters observed. Patients of age <18 years, not consenting to be part of the study, with a history of previous surgical intervention at the cannulation site, presence of a central venous catheter (CVC) in the past 72 h (in the same vein in which the present cannulation was planned), signs of infection, wounds and subcutaneous hematoma close to the puncture site, subcutaneous emphysema with cervical extension,

penetrating neck trauma or cervical trauma, and deranged coagulation profile (international normalized ratio >2 and platelet count <50,000/cu. mm) were excluded from the study [Figure 1].

Sample size calculation

Based on the prevalence of acute complications observed in an earlier publication,^[9] with 95% confidence level and 80% power, the minimum sample size was calculated as 28 in each group. The study was proposed to recruit until the sample size of 30 was attained in each group.

Definitions

Operator

Faculty and residents in the ED who were trained in US guided venous cannulation and had successfully placed a minimum of 10 IJV CVCs unsupervised using both approaches were called “Operator.”^[9]

Acute complications

The acute complications accounted for in this study were:

1. Posterior venous wall puncture (PVWP) (ultrasonographic identification of the needle tip or guidewire at any site deeper than the posterior wall of the IJV during cannulation attempts)
2. Skin hematoma
3. Puncture site bleeding (presence of bleeding that persisted after 2 min of active hemostatic compression)
4. Arterial puncture (any pulsatile blood reflux through the needle observed during the procedure)
5. Pneumothorax

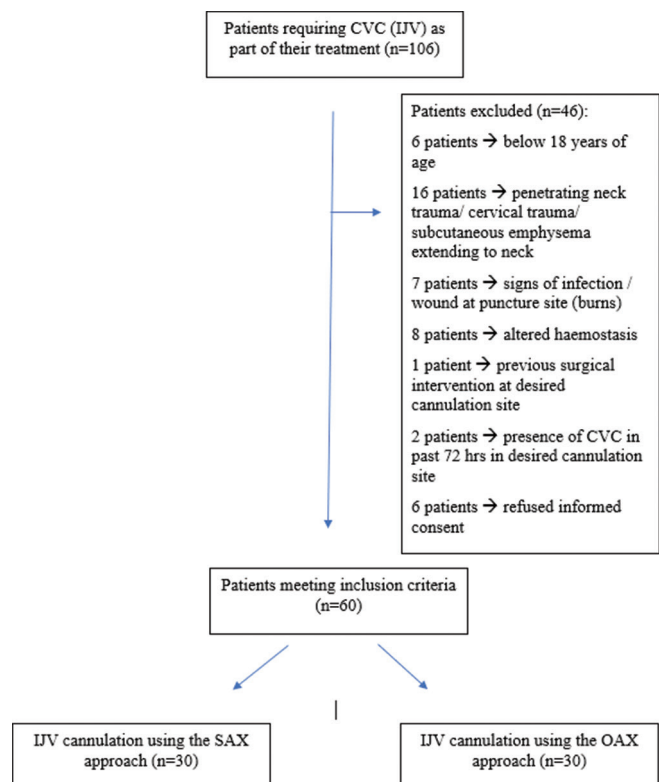


Figure 1: Patient flow diagram

6. Hemothorax
7. Catheter misplacement (catheter tip identified at any place other than the superior vena cava in the control chest radiograph)
8. Cardiac perforation
9. Tracheal injury.

Flash time

The time interval between skin puncture and observing blood at the syringe hub.

Cannulation time

The time interval from skin puncture to catheter tracking over the guidewire.

Successful cannulation

Guidewire advanced without resistance and sonographically detected inside the jugular vein.

Unsuccessful cannulation

A cannulation is considered unsuccessful if it had to be performed using an approach that differed from that to which the patient had been initially chosen for and also if the operator was unable to cannulate the vein within 3 attempts.

Procedure

Using US, the anatomical location and patency of the IJV is assessed with the patient placed in the Trendelenburg position, with the head slightly rotated to the contralateral side.

With all sterile precautions, the region is locally anaesthetized and an 18-gauge introducer needle mounted on a syringe is inserted into the IJV guided by real time US imaging. Once blood is freely aspirated, the US probe is set aside and the syringe removed from the needle. Then the guide wire is advanced through the needle into the vessel and the catheter is advanced using the Seldinger technique after guidewire position is confirmed with US. The guidewire is then removed. Using USG, placement of the catheter in the vein is confirmed following which the catheter is secured in place using sutures. The position of the CVC is also confirmed by a chest radiograph at the end of the procedure.

US guided SAX and OAX approaches to IJV cannulation

SAX approach

The US probe is placed perpendicular to the venous anatomy in the SAX approach [Figure 2a and b].

OAX approach

Here the US probe is aligned at 45° angulation with the venous anatomy, and combined with an in-plane needle insertion technique. The needle is advanced from lateral to medial [Figure 3a and b].

Equipment used

Standard triple lumen CVC was used for cannulation in all patients. The real-time US-guided technique was performed with a single dedicated USG machine (SonoSite Edge® Portable US Machine) and a 13-6 MHz linear probe for the

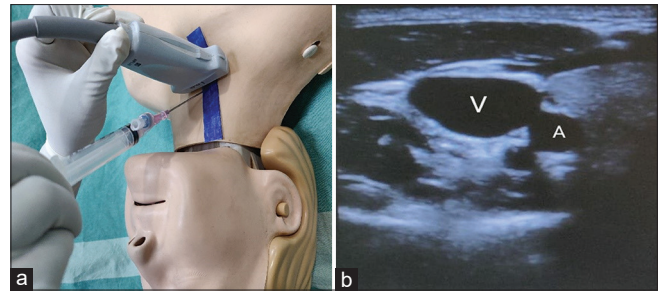


Figure 2: (a) Ultrasound probe placed out of plane with internal jugular vein (image is for representational purposes only). (b) Ultrasound image of vein and artery in short axis approach (V = vein, A = artery)

entire duration of the study. The whole procedure was carried out according to the standard ED protocol.

Data collection process

At the end of each procedure, real time data was recorded which included patient demographics, operator details, method of insertion, indication for central line insertion, acute complications, number of attempts and time to completion (flash time and cannulation time).

Outcome measurement

The primary outcome measured was the number of acute complications with both approaches. The secondary outcomes measured included the flash time, the cannulation time, the number of cannulation attempts and successful cannulation.

Data analysis and interpretation

Numerical variables are expressed as mean \pm standard deviation. Categorical variables are expressed as frequency and percentages. To compare the association of study variables with each technique, Chi-square test was applied. To test the mean differences in the study variables (flash time and cannulation time) between different techniques, Mann-Whitney *U*-test was applied. The statistical software, namely, Statistical Package for the Social Sciences, SPSS; (International Business Machines Statistical Package for the Social Sciences, IBM Corp. Released 2013, Version 22.0. Armonk, NY, USA: IBM Corp) was used for the analysis of the data. Microsoft Word and Microsoft Excel (2013 version) were used to enter data and generate graphs, tables, and charts.

RESULTS

Sixty patients were enrolled in the study; 30 patients had undergone CVC placement by SAX approach and 30 patients by OAX approach.

Most number of patients who required CVCs had a provisional diagnosis of sepsis, septic shock and burns. Patients with polytrauma with hemorrhagic shock were also frequently cannulated with CVCs.

The most common indication for IJV cannulation was the need for volume resuscitation. Other common indications noted were the need for vasopressor infusion, difficulty in obtaining peripheral intravenous lines and lack of alternative

sites (e.g., in burns victims), CVP monitoring and multiple drugs administration [Figure 4].

Right IJV was cannulated in 53 cases (88.3%) with only 7 (11.7%) cannulations done on the left side. In our study, 2 of the 7 (28.5%) cannulations done on the left side had complications.

There were 22 (36.7%) complications in the study: Seventeen (56.7%) in the SAX group ($n = 30$) and 5 (16.7%) in the OAX group ($n = 30$). In the SAX group, PVWP was noted in 50% of cases, accidental arterial puncture in 6.7% of cases, acute pneumothorax, acute haemothorax and subcutaneous haematoma each in 3.3% of cases. In the OAX group, subcutaneous haematoma was noted in 13.3% of cases and puncture site bleeding in 6.7% patients [Table 1].

All (30/30) IJV catheters were successfully inserted using the SAX technique as compared to 93.3% successful insertion using the OAX technique [Table 2].

The catheter was inserted on the first attempt in 45 of 60 (70%) patients; 22 (73.3%) patients in the SAX group and 23 (76.7%) patients in the OAX group. In 9 (15.0%) patients, cannulation was successful only with a second attempt; 6 (20.0%) patients in the SAX group and 3 (10.0%) patients in the OAX group. A third attempt at cannulation was required in 6 (10.0%)

patients; 2 (6.7%) patients in the SAX group and 4 (13.3%) patients in the OAX group [Table 3].

In the OAX group, there were two patients who could not be catheterized even after 3 attempts and were considered as failed attempts. Of the 2 failed catheterizations, which occurred only in the OAX group, crossover to SAX technique was done and access was obtained at a different site.

The mean flash time and cannulation time for the SAX approach was 28.07 ± 17.69 s and 331.83 ± 126.87 s respectively whereas for the OAX technique, it was 26.07 ± 25.17 s and 323.37 ± 162.35 s respectively [Table 4].

Mean flash and cannulation time were calculated for both techniques among all the fifteen operators. Kruskal–Wallis test and analysis of variance were performed. Results showed that there was no statistically significant difference among all the operators in either mean cannulation time ($P = 0.491$) or mean flash time ($P = 0.281$).

Fifteen individuals in the ED met the defined criteria of “experienced operator” and no significant interoperator variability was noted in terms of acute complications ($P = 0.340$) and success rate ($P = 0.479$).

DISCUSSION

A significant decrease in the number of complications between both approaches were noted in our study. The higher complication rate noted with the SAX group in our study may be attributed to the inclusion of the rate of PVWP. In the study done by Wilson *et al.*,^[10] although there was no statistically significant difference in the rates of PVWP, the cannulators revealed greater confidence in the visibility of the needle tip with the OAX technique compared to the SAX approach. Better visualization of both needle tip and the needle track could have contributed to the lower numbers of PVWP with the OAX approach. In a previous study^[11], cannulations done on the left IJV had a higher rate of complications. In our study, of the 7 cannulations done

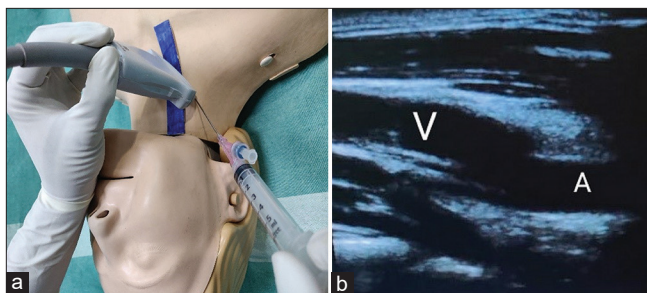


Figure 3: (a) Ultrasound probe placed at 45° angle with internal jugular vein (image is for representational purposes only). (b) Ultrasound image of vein and artery in oblique axis approach (V = vein, A = artery)

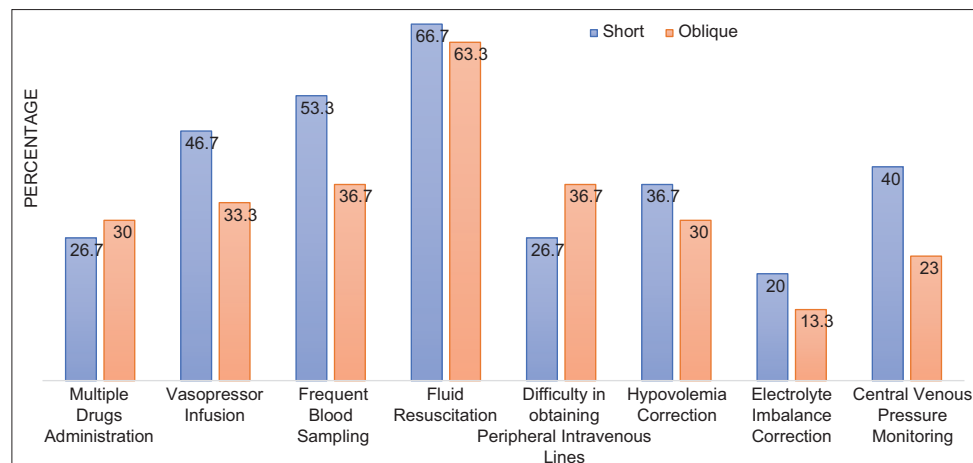


Figure 4: Bar diagram showing indications for CVC Insertion

Table 1: Details of acute complications

Acute complications	Groups		Total, <i>n</i> (%)	<i>P</i>
	Short (<i>n</i> =30), <i>n</i> (%)	Oblique (<i>n</i> =30), <i>n</i> (%)		
Posterior venous wall puncture	15 (50.0)	0	15 (25.0)	<0.001
Acute pneumothorax	1 (3.3)	0	1 (1.7)	0.313
Acute hemothorax	1 (3.3)	0	1 (1.7)	0.313
Arterial puncture	2 (6.7)	0	2 (3.3)	0.150
Subcutaneous hematoma	1 (3.3)	4 (13.3)	5 (8.3)	0.161
Puncture site bleeding	0	2 (6.7)	2 (3.3)	0.150
Catheter malposition	0	0	0	NA
Tracheal injury	0	0	0	NA
Cardiac perforation	0	0	0	NA

NA: Not applicable

Table 2: Success rate comparison

Success rate	Groups		Total, <i>n</i> (%)	<i>P</i>
	Short (<i>n</i> =30), <i>n</i> (%)	Oblique (<i>n</i> =30), <i>n</i> (%)		
Success	30 (100.0)	28 (93.3)	58 (96.7)	0.150
Fail	0	2 (6.7)	2 (3.3)	

Table 3: Comparison of number of attempts for successful cannulation

Number of attempts	Groups		Total, <i>n</i> (%)	<i>P</i>
	Short (<i>n</i> =30), <i>n</i> (%)	Oblique (<i>n</i> =30), <i>n</i> (%)		
1	22 (73.3)	23 (76.7)	45 (75.0)	0.430
2	6 (20.0)	3 (10.0)	9 (15.0)	
3	2 (6.7)	4 (13.3)	6 (10.0)	

Table 4: Comparison of flash time and cannulation time

Variables	Method	<i>n</i>	Mean±SD	<i>P</i>
Flash time	Short	30	28.07±17.69	0.249
	Oblique	30	26.07±25.17	
Cannulation time	Short	30	331.83±126.87	0.420
	Oblique	30	323.37±162.35	

SD: Standard deviation

on the left IJV, 2 cases were noted to have complications. In both the cannulations, the SAX approach was used and PVWP was the noted complication.

A 100% success to cannulation rate was seen in the US guided SAX group while only a 93.3% success rate was noted in the OAX group. No statistical significance was noted. In a study conducted by Batllori *et al.*,^[9] no significant differences in success rate and first needle pass success rate were noted between the SAX and OAX approach. In our study, the reason for observing similar success rates with either techniques might be due to the experience of the operators.

In the first attempt 73.3% of the cannulations done with SAX approach and 76.7% of the cannulations done with

the OAX approach were successful. A third attempt at IJV catheterization was required in two cases done with the SAX approach as compared to 4 cases done with the OAX approach. In these six cannulations requiring a third attempt, complications such as subcutaneous haematoma and puncture site bleeding were noticed. Of the four cases done with the OAX approach that required three attempts, the operator had to change to the US-guided SAX approach to complete IJV cannulation in 2 cases. Difficulty in cannulation was observed more in cases with anatomical limitations (as neck length) to obtain a 45° angulation of the US probe while performing the OAX approach. In a study focused on^[12] reviewing CVC complications, the incidence of complications after 3 or more insertion attempts was 6 times greater than a single attempt. Therefore, the number of attempts to successful venipuncture and catheter placement is important.

Although the time to cannulation was not statistically significant (*P* = 0.420), the SAX approach required more time to cannulation (331.8 ± 126.8 vs. 323.3 ± 162.3 s). This finding is consistent with previous studies. The time to cannulation has no bearing on the success of the procedure.

In terms of demographic data, no significant difference was noted between the groups.

Limitations

In our study, PVWP was determined by sonographically visualizing the needle tip beyond the posterior wall of the IJV at any point in the procedure and it is possible that in many cases, an artifact may have been mistaken for the needle tip leading to the higher incidence of this complication.

Although an experienced operator was arbitrarily defined as having performed more than 10 successful IJV catheter insertions with both approaches, this may not truly reflect the experience of the operator. The SAX approach was the preferred approach by most operators. Differences in the ability of each operator to manage both approaches have also been considered as a possible source of bias, which we have attempted to minimize by ensuring we used experienced operators for both techniques. Nonetheless, no differences were

detected between operators regarding their quality and safety of cannulation outcomes. This study was done with experienced operators; hence, the learning curve to the OAX approach for novice users of US could not be assessed.

CONCLUSION

US guided OAX approach when compared with the SAX approach, is helpful in preventing acute complications, as PVWP, due to the advantage of full visualization of the needle. The SAX approach fared better in terms of success rate of cannulation. Number of attempts at cannulation and access times had no significant differences between the two approaches.

In ED's where USG is available, residents and faculty members may be regularly trained in the use of the OAX approach, due to its potential benefits in preventing complications. Further multicentric studies in this regard needs to be done across operators to establish the potential benefits of the OAX view.

Acknowledgment

The authors would like to acknowledge Mr. Unnikrishnan for his contribution to statistical analysis and Dr. Dipin Dinesh I for his contribution to the pictorial representations.

Financial support and sponsorship

Nil.

Conflicts of interest

There are no conflicts of interest.

REFERENCES

1. Roberts JR, Hedges JR. Roberts and Hedges' Clinical Procedures in Emergency Medicine E-Book. Amsterdam, Netherlands: Elsevier Health Sciences; 2013.
2. Brass P, Hellmich M, Kolodziej L, Schick G, Smith AF. Ultrasound guidance versus anatomical landmarks for internal jugular vein catheterization. *Cochrane Database Syst Rev* 2015;1:CD006962.
3. Phelan M, Hagerty D. The oblique view: An alternative approach for ultrasound-guided central line placement. *J Emerg Med* 2009;37:403-8.
4. Dilisio R, Mittnacht AJ. The "medial-oblique" approach to ultrasound-guided central venous cannulation--maximize the view, minimize the risk. *J Cardiothorac Vasc Anesth* 2012;26:982-4.
5. Ho AM, Ricci CJ, Ng CS, Critchley LA, Ho AK, Karmakar MK, *et al.* The medial-transverse approach for internal jugular vein cannulation: An example of lateral thinking. *J Emerg Med* 2012;42:174-7.
6. French JL, Raine-Fenning NJ, Hardman JG, Bedforth NM. Pitfalls of ultrasound guided vascular access: The use of three/four-dimensional ultrasound. *Anaesthesia* 2008;63:806-13.
7. Blaivas M, Adhikari S. An unseen danger: Frequency of posterior vessel wall penetration by needles during attempts to place internal jugular vein central catheters using ultrasound guidance. *Crit Care Med* 2009;37:2345-9; quiz 2359.
8. Chittoodan S, Breen D, Iohom G. Long versus short axis ultrasound guided approach for internal jugular vein cannulation: A prospective randomised controlled trial. *Med Ultrason* 2011;13:21-5.
9. Batllori M, Urrea M, Uriarte E, Romero C, Pueyo J, López-Olaondo L, *et al.* Randomized comparison of three transducer orientation approaches for ultrasound guided internal jugular venous cannulation. *BJA Br J Anaesth* 2015;116:370-6.
10. Wilson JG, Berona KM, Stein JC, Wang R. Oblique-axis vs. short-axis view in ultrasound-guided central venous catheterization. *J Emerg Med* 2014;47:45-50.
11. Sulek CA, Blas ML, Lobato EB. A randomized study of left versus right internal jugular vein cannulation in adults. *J Clin Anesthesia* 2000;12:142-5.
12. McGee DC, Gould MK. Preventing complications of central venous catheterization. *N Engl J Med* 2003;348:1123-33.